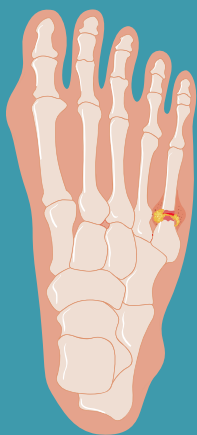


# Complications and Management of Jones Fractures



**Jones fracture**  
Fracture of the 5th metatarsal at the metaphyseal-diaphyseal junction

## Orthopaedic management

### Non-surgical



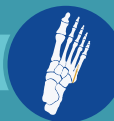Cast



Boot immobilization

### Surgical

Intramedullary screw fixation



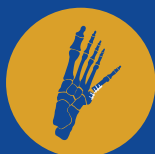Plantar lateral plate fixation



## Complications of Jones fractures



Refracture



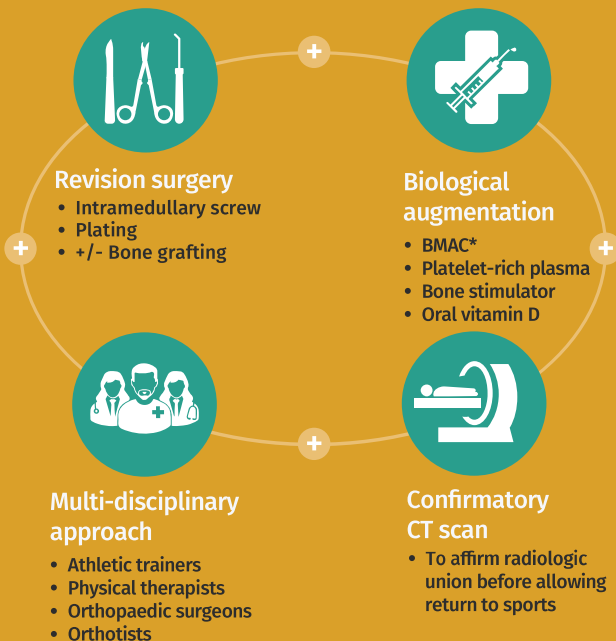
Non-union



Delayed union



## Prevention and treatment of complications



\*BMAC = Bone Marrow Aspirate Concentrate



Jones fractures can develop subsequent complications despite good operative fixation, necessitating supplementation of surgical management with biological augmentation and a multi-disciplinary approach to ensure better patient outcomes